



## VERTICAL FIGURE-OF-EIGHT STITCHES FOR SURGICAL CLOSURE OF LAPAROTOMIES IN THE RAT

Blanco E<sup>1</sup>, Aller M A<sup>2</sup>, Ortega L<sup>3</sup>, Sánchez-Patán F<sup>2</sup>, de Vicente F<sup>2</sup>, Nava M P<sup>4</sup>, González P<sup>5</sup>, Arias J<sup>1</sup>

<sup>1</sup> Vascular Surgery Department. San Carlos University Hospital. Madrid.Spain.

<sup>2</sup> Surgery Chair. Surgery I Department. Medical School. Complutense University. Madrid. Spain.

<sup>3</sup> Pathology Department. San Carlos University Hospital. Madrid. Spain.

<sup>4</sup> Physiology (Animal Physiology II). Biology School. Complutense University. Madrid. Spain.

<sup>5</sup> Experimental Medicine and Surgery. San Carlos University Hospital. Madrid.Spain

### KEY WORDS:

laparotomy, suture, rat.

### Correspondence:

MARIA ANGELES ALLER  
Cátedra de Cirugía. Facultad de Medicina  
Universidad Complutense  
Pza. de Ramón y Cajal s.n.  
28040 MADRID. Spain  
Phone: +34 91 3941388 • Fax: +34 91 3947115  
e-mail: maaller@med.ucm.es

### ABSTRACT

*Surgical closure of laparotomies can result in short- and long-term postoperative complications such as tissue reactivity, wound dehiscence, infections and incisional hernia. In order to decrease these complications we propose a new suture technique which associates the continuous suture of the cutaneous and musculoaponeurotic layers maintaining individuality in the anatomical reconstruction of each layer.*

*Midline laparotomy incisions in rats were closed with either a conventional running suture into two layers with Polyglactin 910 (Vicryl®) and silk (Group 1; n=11) or a continuous vertical figure-of-eight stitches with Polyglycolic acid (Safil®) (Group 2; n=11). Both groups were studied at 28 days of evolution.*

*The time required for the laparotomy closure was higher ( $p<0.05$ ) in Group 1. The suture length ( $p<0.05$ ) was longer in Group 1. One rat from Group 1 suffered a wound dehiscence. Adhesions were more frequent in Group 1. The inflammatory reaction around the suture was greater in Group 1 than in Group 2.*

*The new continuous suture technique using vertical figure-of-eight stitches to close a midline laparotomy in the rat reduces the incidence of postoperative complications and is faster, easier to perform and reduces the amount of suture material as well as the tissue reactivity compared to the conventional two layer suture.*

### INTRODUCTION

Surgical closure of laparotomies involves surgical trauma and the presence of suture material, which acts as foreign body, and both factors trigger an inflammatory reaction that may be excessive, producing a weak scar and can negatively affect the immune response against infections. The normal process of wound healing is, therefore, altered leading to potential wound dehiscence<sup>1</sup>.

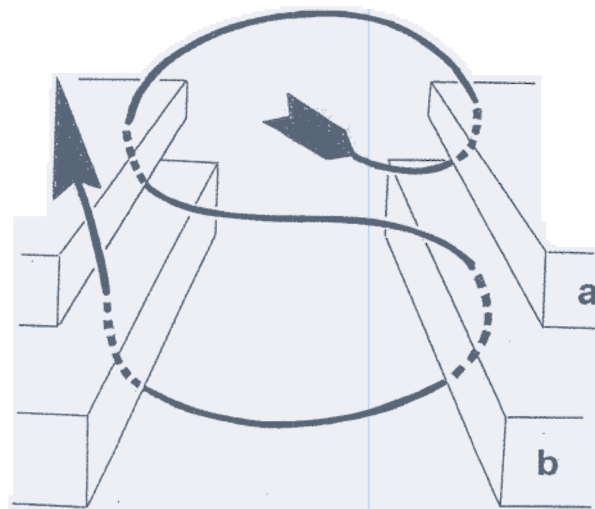
For this reason, it is essential to consider which measures would be the most useful to reduce the risk of both short- and long-term postoperative complications. The most important short-term complications are tissue reactivity, wound dehiscence and infections. The most serious late complication is incisional hernia, with a reported cumulative incidence of 9 to 19%<sup>2,3,4</sup>. Incisional hernias often require repair, with postoperative recurrence rates as high as 45%<sup>5</sup>, further contributing to complications. At the worst, immediate reoperation is necessary, with death in 18-35% of cases<sup>6-10</sup>.

Wound healing, and especially the healing of laparotomies, is a multifactorial process in which the closing technique, which can be influenced by the surgeon<sup>11-14</sup>, plays a central role<sup>13,15</sup>. Thus, delicate tissue handling, suture tension, choice of suture material, and choice of the most suitable suturing technique could be considered to play an important role in reducing the risk of complications<sup>16</sup>.

In order to reduce these complications, a new suture technique of midline laparotomy closure in the rat is proposed. This technique associates the advantage of continuous suture of the cutaneous and musculoaponeurotic layers with the maintenance of individuality in the anatomical reconstruction of each plane.

## MATERIALS AND METHODS

Twenty-two female Wistar rats from the Vivarium of San Carlos University Hospital of Madrid, with body weights from 250 to 300 g, were used. All the animals were maintained under constant conditions. Room temperature was kept at  $20 \pm 2^\circ\text{C}$ , with relative humidity of  $65 \pm 10\%$  and an artificial light-dark cycle of 12 h. (08.00-20.00 h / 20.00-08.00 h). An air-conditioning system guaranteed air heating, cooling and renewal in the room. Each animal was housed individually in polycarbonate cages (43 x 27 x 17 cm, Leticia®, Spain). All the animals had free access to standard rodent feed (rat/mouse A04 maintenance diet, Panlab®, Spain. www.panlab-sl.com) -that is in accordance to the Nutrient Requirements of Laboratory Animals, Fourth Revised Edition, 1995- and tap water ad libitum.



**Figure 1.-** Figure-of-eight stitch which is used in proximal and distal. The cutaneous or superficial loops alternate with the deep or musculoaponeurotic loops.

The experimental procedures employed in this study are in accordance with the European Convention for the protection of vertebrate animals used for experimental and other scientific purposes (Guidelines for the Care and Use of Laboratory Animals, 1986), published in Spain (Royal Decree 223/1988).

## EXPERIMENTAL DESIGN

The animals were randomized in two Groups of eleven animals each. Group 1 was comprised by rats in which a midline laparotomy was closed with a continuous conventional running suture on two layers. Group 2 is made up by rats in which a midline laparotomy was closed using a new technique of continuous suture with vertical figure-of-eight stitches (Figure 1).

The experiments were developed under general anesthesia with Ketamine (90 mg/Kg) and Xylazine (10 mg/kg) 17. The abdomen was clipped of hair, and by a clean technique, a midline abdominal incision was made from xyphoid to symphysis pubis (7 cm). The skin and superficial fascia were reflected off 2 cm lateral to the incision and the abdominal fascia was marked with the aid of a standard template. Then, a laparotomy of 6 cm was performed.

## SUTURE TECHNIQUES


In Group 1, closure of the laparotomy was done on two layers: musculoaponeurotic and cutaneous. The sites of entry of the sutures were marked on the musculoaponeurotic layer with a template and indelible ink. First, a continuous mass closure technique encompassing all layers of the abdominal wall except the skin was made. This peritoneal-muscular-fascial layer was surgically closed using a braided synthetic absorbable suture (Poliglactin 910, Vicryl®), suture size was USP (United States Pharmacopoeia) 3/0, the stitch interval was 1 cm and the stitches were at 5 mm from the incisional edge. The number of stitches was 6. The length of the suture and the length of the wound were measured to calculate the suture length:wound length ratio (SL:WL). The initial and final stitches were secured with three non-identical sliding knots just approximating the incisional edges without tissue overlapping. Then, the skin was closed with continuous non-absorbable suture (3/0 silk). The number of stitches was 7, the distance between stitches was 1 cm and the stitches were at 2 mm from the incisional edge.

In Group 2, all the layers of the abdominal wall were closed using a new suture method which consisted in a continuous technique with stitches called figure-of-eight as each one is comprised of a superficial or cutaneous loop and a deep or musculo-aponeurotic loop (Figure 2a). The suture is early absorbable synthetic braided multifilament of polyglycolic acid of low molecular weight coated with magnesium stearate (Safil®, BBraun Aesculap, Barcelona, Spain; USP 3/0). The first loop approaches the cutaneous edges of the wound. The suture thread passes through one edge of the skin from the inside to the outside and then passes through the opposite edge from the outside to inside and both sutures are separated by 2 mm from the wound edge (Figures 2a and 2b). The deep loop approaches the musculoaponeurotic edges of the incision. The suture thread passes through the anterior fascia, and then through the posterior fascia, muscle and anterior fascia, all of which are at 5 mm equidistant from the wound edge (Figures 2a and 2b).

The superficial loop of the suture causes the inversion of the cutaneous edges and the deep loop of the suture causes the eversion of the musculoaponeurotic edges. Superposition of the cutaneous and musculoaponeurotic stitches (Figures 2a and 2b) is avoided by using the alternative cutaneous and musculoaponeurotic suture, in which all the stitches are separated from each other by 1 cm intervals. The cutaneous stitches are tied with four alternating sliding knots with different patterns at the beginning and at the end of the suture.

## POSTOPERATIVE EVOLUTION

After closure of the laparotomy wound, this was covered during the first 7 days with a gauze with povidone-iodine to prevent the animal from wounding itself. Amoxicillin (100 mg)



**Figure 2.-** a: proximal vertical stitch in figure-of-eight shape with a superficial or cutaneous loop and a deep or musculoaponeurotic loop. b: End of the continuous suture with an interior knot. The cutaneous or superficial loops alternate with the deep or musculoaponeurotic loops.

**HISTOLOGICAL MEASURES USED TO ASSESS TISSUE REACTION**

**Table I.**

MEASURE	WEIGHING FACTOR
Width of inflammation zone, mm*	
Overall cell density +	
No. of cells in inflammatory zone +	
- Neutrophils	6
- Multinucleated giant cells	2
- Fibroblasts	1
- Lymphocytes	2
- Macrophages	
- Mononuclear phagocytes	

\* Graded on a scale of 1 to 8, where 1 indicates a diameter of 0.01 to 0.25 (in high-power fields, x430) and 8, 4.1 or greater.

+ Graded on a scale of 1 to 8, where 1 indicates a bare scattering of inflammatory cells and 8, a dense aggregation.

and magnesium metamizole (2 mg) were administered v.o./day during 7 days.

During the postoperative the incidence of complications was observed: hemorrhage, seroma, wound infection (purulent discharge from the wound), Wound dehiscence (failure to close the abdominal wall-peritoneum and the early appearance of fascia with integrity or not of the cutaneous suture), incisional hernia (dehiscences of the fascia which occur late that are, generally, associated with integrity of the peritoneum and the skin).

The 28<sup>th</sup> day of the postoperative evolution inhalatory anesthesia with halothane was induced and an inverted incision in "U" was made from xyphoid to the pubis. After this, the macroscopic appearance of the wound was observed, as well as the existence of adhesions. Randomly selected wound segments were fixed in formalin (10%) and stained with hematoxylin-eosin for histologic study in a blinded fashion. All cuts were made midway between sutures perpendicular to the direction of the wound. Finally, the animals were sacrificed by halothane overdose.

To assess the tissue reaction, the scoring system of Sewell et al.<sup>18</sup> was adopted. This assigns a total tissue reactivity score by assessing 8 variables, as illustrated in **Table I**. The average values are calculated for each variable, graded, multiplied by a specific weighting factor, and summed, resulting in the total tissue reactivity score. Accordingly, the overall grade of tissue reaction is read (**Table II**).

Statistical analysis was done with the Statistical Package for the Social Science software (SPSS® 8.0) software. Student's t-test for independent data was used for the comparison of variables between the two groups. Adhesion incidence between the two groups was compared with the Chi-squared test. A probability of less than 0.05 was accepted as significant.

**RESULTS**

The time required for laparotomy closure was higher (p<0.05) in Group 1, in which a conventional continuous running suture was made compared to Group 2 with a continuous suture using vertical figure-of-eight stitches (**Table III**).

The suture length (p<0.05) was longer in Group 1 compared to Group 2 (**Table III**) and the SL:WL ratio was 2 in Group 1 and 3 in Group 2.

No hemorrhage, seroma or incisional hernia occurred in any of the animals. Although a clean rather than sterile technique was used there were no skin infections or deep wound

Table II.

ASSIGNMENT OF THE OVERALL GRADE OF TISSUE REACTION (CRITERIA FOR TISSUE REACTIVITY DEMARCATION)

TOTAL POINTS	GRADE OF TISSUE REACTION	NAME ASSIGNED TO GRADE
0-16	1	Very Slight
17-32	2	Slight
33-48	3	Slight to moderate
49-64	4	Moderate
65-80	5	Moderate to marked
81-96	6	Marked
97-112	7	Marked to extensive
>112	8	Extensive

Table IV.

POSTOPERATIVE COMPLICATIONS IN GROUP 1, IN WHICH THE LAPAROTOMY WAS CLOSED BY A CONTINUOUS SUTURE ON TWO LAYERS, AND IN GROUP 2 WITH CONTINUOUS SUTURE WITH FIGURE-OF-EIGHT VERTICAL STITCHES.

	WOUND DEHISCENCE	ADHESIONS TO PERITONEUM	ADHESIONS TO INTESTINE	TOTAL
Group 1 (n=11)				10 (90.9%)
Group 2 (n=11)	0	4 (36.36%)	2 (18.18%)	6 (54.54%)

infections. One rat from group 1 suffered a wound dehiscence on the 10<sup>th</sup> day of evolution (Table IV). Adhesions were present in 10 rats belonging to Group 1, of which 4 rats showed adhesions between the abdominal wall and peritoneum, 5 rats showed adhesions between the abdominal wall and intestine and 1 rat showed adhesions to both intestine and peritoneum. In Group 2, adhesions developed in 6 rats, in 4 rats these consisted of adhesions to peritoneum and in 2 rats to the intestine (Table IV). Although there is a greater incidence of adhesions in rats from Group 1 (n=10) compared to the rats from Group 2 (n=6) the difference was not statistically significant (p=0.06).

Histologically, the tissue reaction to the suture consisted of edema, i.e., the formation of an inflammatory zone around the suture. The reaction was mainly a neutrophilic infiltration accompanied by a monophagocytic invasion although by the 28th day the degree of exudation was low and fibroplasia was usually predominant. In Group 1 an extensive inflammation was present around the suture, with abundant giant cells, neutrophils and lymphocytes, muscle bundles were necrotic and there was a greater development of connective periinflammatory tissue. On the contrary, in Group 2 there was a

Table III.

DURATION OF OPERATION, SUTURE LENGTH AND SUTURE LENGTH:WOUND LENGTH RATIO (SL:WL) IN GROUP 1, IN WHICH THE LAPAROTOMY WAS CLOSED BY A CONTINUOUS SUTURE ON TWO LAYERS AND IN GROUP 2, WITH CONTINUOUS SUTURE WITH VERTICAL FIGURE-OF-EIGHT STITCHES

	DURATION OF OPERATION (min)	SUTURE LENGTH (cm)	SL:WL
Group 1 (n=11)	5,13±0,33		2
Group 2 (n=11)	3,07±0,14*	18.536±0.9811*	3

+ Musculoaponeurotic layer: 13.682±0.9358 cm ; cutaneous layer: 13.818±0.8875 cm

\* p<0.05: statistically significant value of group 2 in regards to group 1

moderate infiltration of lymphoid cells and neutrophils with few giant cells with well preserved muscle architecture. We assessed the inflammatory reaction using the scoring system of Sewell et al<sup>18</sup>. In Group 1, the overall grade of tissue reaction frequently varied between marked, marked to extensive and extensive (Table II). One rat had grade 8, eight rats grade 7, and two rats grade 6 (Figure 3). In Group 2, the overall grades of tissue reaction frequently varied between moderate and slight to moderate. One rat had grade 6, seven rats grade 4, two rats grade 3 and one rat grade 1 (Figure 3).

DISCUSSION

The new continuous suture technique using vertical figure-of-eight stitches to close a midline laparotomy in the rat reduces the incidence of postoperative complications and is

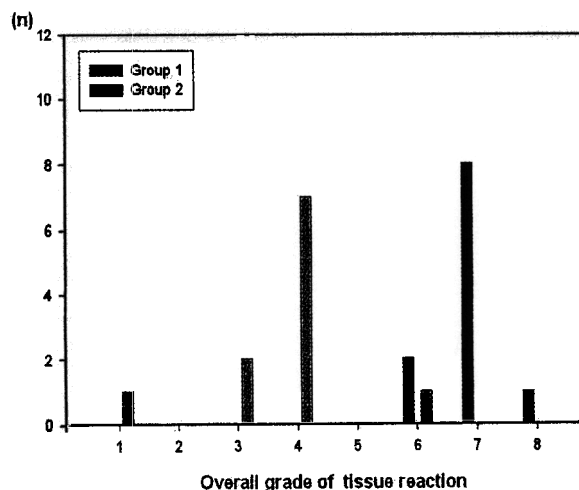


Figure 3.- Overall grade of tissue reaction in Group 1, in which the laparotomy was closed by a continuous suture on two layers, and in Group 2 with continuous suture with figure-of-eight vertical stitches.

also faster, easier to perform and reduces the amount of suture material in the wound and the tissue reaction in comparison to conventional continuous two layer sutures.

Wound infection, abdominal distension, operation time and systemic factors affect the quality of wound healing but some of them can be influenced by the surgeon<sup>11-14</sup>. Randomized controlled trials of abdominal closure have failed to determine the best technique and the ideal suture which, as well as fomenting the use of meta-analyses<sup>10</sup>, explains why the researchers continue developing numerous clinical and experimental studies to try to reduce the complications of wound healing that can be controlled by the surgeon.

Despite the differences that exist in the physiology of the abdominal wall in the rat and in the human being (less intra-abdominal pressure and postural differences), wound healing and incisional hernia formation in the rat closely resembles that in the human patient<sup>19</sup>.

The incidence of postoperative complications in this study was low possibly, among other reasons, because we used a continuous suture. It has been proved that continuous mattress suturing after laparotomy is beneficial in terms of wound healing and also means significantly shorter operating times and smaller amounts of suture material are needed. Combined with suture length-to-wound length ratios of at least 4:1 and low suture tension, this technique is superior to single interrupted suturing as its bio-mechanical properties are better and it allows better collagen synthesis in the region of the incision<sup>20,21</sup>. Interrupted single sutures do not take over the tensile forces acting upon the incision as effectively as running sutures do. The result is mechanical stress on the newly developed collagen and larger fibril diameters which hamper tissue restructuring<sup>22</sup>.

The ideal closure technique of laparotomy wounds should combine a reliable mechanical performance to maintain approximation of the wound edges, with strength to prevent rupture, and elasticity to accommodate increased abdominal pressure in the postoperative period<sup>23</sup>. Apparently, an unsuitable surgical technique is the most important factor in the development of dehiscences<sup>23</sup>. Technical errors include the use of small stitches (with only a short distance from the stitches to the edge of the fascia), very separate stitches and excess tension<sup>24</sup>.

With the new technique of laparotomy closure with vertical figure-of-eight stitches (**Figure 2**) proposed here, there was no case of wound dehiscence or of incisional hernia. Niggebrugge et al. describe a continuous double-loop closure in which the outer loop, which contains more tissue than the inner loop, pulls the inner loop tight if tensile forces on the wound increase<sup>15</sup>. A similar phenomenon occurs with our technique of vertical figure-of-eight stitches since when there is distension of one of the layers the tension of the other increases. A possible explanation for the greater resistance to the high pressure is that with the new technique the suture behaves like a spiral. This is effective because it distributes the tension uniformly along the two layers, cutaneous and musculoaponeurotic, but maintains approximation of the wound edges. Wound-edge separation interferes with healing and makes the wound more susceptible to dehiscence<sup>15</sup>.

In continuous closure of midline laparotomy incisions, the suture length:wound length ratio (SL:WL) should be four or more, because a lower ratio is associated with an increased

rate of incisional hernia<sup>25-27</sup>. The SL:WL ratio depends on the interval between stitches, and the stitch length. Although in the new technique proposed the SL:WL ratio is 3, there was no case of wound dehiscence, and hence it does not seem necessary to increase the stitch length because of the risk of infection and incisional hernia associated with this approach<sup>26</sup>. Therefore, continuous suture of midline laparotomies in the rat with SL:WL ratio of less than 4 with a suture tension that leads to a close adaptation of fascial edges is a suitable technique when vertical figure-of-eight stitches are used. It is possible that a SL:WL ratio of 3 in the rat ensures an adequate reserve of suture length to adapt to the abdominal distension that may occur after operation, which is lower in this animal than in humans<sup>19</sup>.

An additional advantage with the new technique described is that only two knots are necessary to secure all the wound, thus reducing the weakest part of the suture<sup>28-30</sup>. This is one of the factors that permits this suture to be done in 40% less time (**Table III**) than the conventional closure technique in two layers.

When surgical procedures are performed, the surgical trauma and the presence of suture materials, which act as a foreign body, trigger an inflammatory reaction that may be excessive producing a weak scar, and that may negatively affect the immune response against infections<sup>31,24</sup>. Soluble immunologic factors from suture materials influence macrophage behavior causing cellular activation, functional impairment and alterations in secreted levels of the cytokine tumor necrosis factor and the bactericidal agent lysozyme<sup>32</sup>. Particularly, polyglactin and silk cause significant inhibition of cell adherence and lysozyme production<sup>32</sup>. None of the animals from the two groups studied presented infection of the surgical wound possibly owing to the antibiotic treatment and because a lower incidence of early infections has been described in patients where modern absorbable materials were used<sup>33</sup>. However, the greater the amount of foreign material introduced in the wound, the greater the predisposition to infection<sup>34</sup>, and the stimulus that triggers inflammatory reactions. Thus, in Group 2, in which 33% less suture material was used, the inflammatory changes (**Figure 3**) were less pronounced and the architecture of the regenerative tissue was homogeneous with highly active fibroblasts. The greater mechanical irritation of the tissue in Group 1 should act by impairing the reparative process and, finally, lead to reduced mechanical properties of the developing scar. This may explain why one rat from Group 1 suffered a wound dehiscence.

This high incidence of peritoneal adhesions is noteworthy and this is greater in the animals belonging to Group 1, of conventional suture (**Table IV**). The development of peritoneal adhesions after abdominal surgery is a common cause of morbidity and can, especially, lead to intestinal occlusion, infertility, abdominal pain and reintervention<sup>34</sup>. Ischemia, produced by grafting or tight suturing, is the strongest stimulus for the formation of peritoneal adhesions<sup>35</sup> because the peritoneum loses its ability to lyse fibrin but also may actively inhibit fibrinolysis by normal tissues<sup>36</sup>. It has been demonstrated that two different stimuli are required for adhesion formation: a direct lesion of the mesothelial layer and a foreign body which acts as a substrate<sup>37</sup>. The accidental entry of foreign bodies into the abdomen during surgery is frequent and it could shift the balance between the mechanisms promoting healing of the injured mesothelial surface (mesothelial cell proliferation) and

those promoting adhesions (inflammatory response and fibroblast activation) toward the latter<sup>37</sup>.

In this study, a new early absorbable suture material of polyglycolic acid (Safil®) is used. This material maintains 50% of the initial tensile resistance for 7 days and is completely absorbed by the 42<sup>nd</sup> day. Since it is made from pure polyglycolic acid this is absorbed by hydrolysis without inducing an inflammatory reaction. Polyglactin 910 (Vycril®) showed an increased tissue reactivity (Figure 3) when compared with polyglycolic acid and this could result from a presumed protective action promoted by the degradation products of polyglycolic acid<sup>38</sup>. Undoubtedly, the perfect suture material<sup>39,40</sup> has not yet been found although Safil® could have some of its properties.

In conclusion, because of the reduced incidence of complications, the reduced time consumption, the reduction in the amount of foreign material in the wound, that leads to less stimulus for the inflammatory reaction and infection, its lower cost and the equilibration of tension along the length of the wound, this new technique of continuous vertical figure-of-eight stitches appears to be preferable to conventional suture techniques in two layers for the closure of abdominal wounds in the rat.

#### ACKNOWLEDGEMENTS

We wish to thank BBraun Aesculap (Barcelona, Spain) for donating the Safil Quick® and Caroline Coope, who translated the manuscript.

#### REFERENCES

- 1 Smit JB, Witte E, Brand R, Trimboos JB. Tissue reaction to suture materials revisited: Is there argument to change our views? *Eur Surg Res* 23: 347-54, 1991
- 2 Mudge M, Hughes LE. Incisional hernia: a 10-year prospective study of incidence and attitudes. *Br J Surg* 72: 70-71, 1985
- 3 Osther PJ, Gjode P, Mortensen BB et al. Randomized comparison of polyglycolic acid and polygluconate sutures for abdominal fascial closure after laparotomy in patients with suspected impaired wound healing. *Br J Surg* 82: 1080-1082, 1995
- 4 Israelsson LA, Johnsson T. Incisional hernia after midline laparotomy: a prospective study. *Eur J Surg* 162: 125-129, 1996
- 5 Gecin E, Kocak S, Ersch S. Recurrence after incisional hernia repair: results and risk factors. *Surg Today* 26: 607-609, 1996
- 6 Mayo CW, Lee MJ. Separations of abdominal wounds. *Arch Surg* 62: 883-894, 1951
- 7 Efron G. Abdominal wound disruption. *Lancet* 1: 1287-1291, 1965
- 8 Kirk RM. Effect of method of opening and closing the abdomen on incidence of wound bursting. *Lancet* 19: 352-353, 1972
- 9 Riou JPA, Cohen JR, Johnson H. Factors influencing wound dehiscence. *Am J Surg* 163: 324-330, 1992
- 10 Hodgson NCF, Malthaner RA, Ostbye T. The search for an ideal method of abdominal fascial closure. A meta-analysis. *Ann Surg* 231: 436-442, 2000
- 11 Stelzner F. Theory and practice of continuous laparotomy suture (abdominal wound dehiscence and incisional hernia). *Chirurgie* 59: 654-660, 1988
- 12 Wadstrom J, Gerdin B. Closure of the abdominal wall: how and why? *Clinical review. Acta Chir Scand* 156: 75-82, 1990
- 13 Rath Am, Chevrel JP. The healing of laparotomies: review of the literature. *Hernia* 2: 145-149, 1998
- 14 Schumpelick V, Kingsnorth AN. Closure of laparotomy. In: *Incisional hernia, part V. Berlin, Heidelberg, New York, Springer pp 231-234, 1999*
- 15 Niggebrugge AHP, Trimboos JB, Hermans J, Knippenberg B, Van de Velde CJH. Continuous double loop closure: a new technique for repair of laparotomy wounds. *Br J Surg* 84: 258-261, 1997
- 16 Gabrielli F, Potenza C, Puddu P, Sera F, Masini C, Abeni D. Suture materials and other factors associated with tissue reactivity, infection, and wound dehiscence among plastic surgery outpatients. *Plast Reconstr Surg* 107: 38-45, 2001
- 17 Waynforth H B, Flecknell PA. *Experimental and Surgical Technique in the rat.* London Academic Press Ltd, 1999
- 18 Sewell WR, Wiland J, Craver BN. A new method of comparing sutures of ovine catgut with sutures of bovine catgut in three species. *Surg Gynecol Obstet* 100: 483-494, 1955
- 19 Höer J, Klinge U, Schachtrupp A, Töns C, Schumpelick V. Influence of suture technique on laparotomy wound healing: an experimental study in the rat. *Langenbeck's Archives of Surgery* 386: 218-223, 2001
- 20 Höer J, Stumpf M, Rosch R, Klinge U, Schumpelick V. prevention of incisional hernia. *Chirurgie* 73: 881-887, 2002
- 21 Höer JJ, Junge K, Schachtrupp A, Klinge U, Schumpelick V. Influence of laparotomy closure technique on collagen synthesis in the incisional region. *Hernia* 6: 93-98, 2002
- 22 Höer JJ, Anurov M, Titkova S, Klinge U, Töns C, Öttinger A, Schumpelick V. Influence of suture material and suture technique on collagen fibril diameters in midline laparotomies. *Eur Surg Res* 32: 359-367, 2000
- 23 Niggebrugge AHP, Trimboos JB, Hermans J, Steup W-H, Van de Velde CJH. Influence of abdominal wound closure technique on complications after surgery: a randomized study. *Lancet* 353: 1563-1567, 1999
- 24 Sanders RJ, Ciclementi D. Principles of abdominal wound closure. II. Prevention of wound dehiscence. *Arch Surg* 112: 1188-1191, 1997
- 25 Jenkins TP. The burst abdominal wound: a mechanical approach. *Br J Surg* 63: 873-876, 1976
- 26 Kendall SW, Brennan TG, Guillou PJ. Suture length to wound length ratio and the integrity of midline and lateral paramedian incisions. *Br J Surg* 78: 705-707, 1991
- 27 Israelsson L, Jonsson T. Suture length to wound length ratio and healing of midline laparotomy incisions. *Br J Surg* 80: 1284-1286, 1993

- 28 Tera H, Aberg C. Strength of knots in surgery in relation to type of knot, type of suture material and dimension of suture thread. *Acta Chir Scand* 143: 75-83, 1977
- 29 Pollock AV, Greenall MJ, Evans M. Single-layer mass closure of major laparotomies by continuous suturing. *J R Soc Med* 72: 889-893, 1979
- 30 Trimbos JB. Security of various knots commonly used in surgical practice. *Obstet Gynecol* 64: 274-280, 1984
- 31 Israelsson LA, Jonsson T, Knutsson A. Suture technique and wound healing in midline laparotomy incisions. *Eur J Surg* 162: 605-609, 1996
- 32 Uff CR, Scott AD, Pockley AG, Phillips RK. Influence of soluble factors on in vitro macrophage function. *Biomaterials* 16: 355-360, 1995
- 33 Bohanes T, Neoral C, Klein J, Havlik R, Aujesky R, Kral V. Role of modern absorbable suture materials in decreasing the occurrence of early complications after laparotomy. *Rozhl Chir* 81 (Suppl 1): S24-26, 2002
- 34 Mc Neill PM, Sugerman HJ. Continuous absorbable vs interrupted nonabsorbable fascial closure. *Arch Surg* 121: 821-823, 1986
- 35 Kapur ML, Daneswar A, Chopra P. Evaluation of peritoneal closure at laparotomy. *Am J Surg* 137: 650-652, 1979
- 36 Buckman RF Jr, Buckman PD, Hufgel HV, Gervin AS. A physiological basis of adhesions: free healing of deperitonealized surfaces. *J Surg Res* 21: 67-72, 1976
- 37 Torre M, Favre A, Pini Prato A, Brizzolara A, Martucciello G. Histologic study of peritoneal adhesions in children and in a rat model. *J Pediatr Surg* 18: 673-676, 2002
- 38 Hermann JB, Kelly EJ, Higgins GA. Polyglycolic acid sutures: laboratory and clinical evaluation of a new absorbable suture material. *Arch Surg* 100: 486-490, 1970
- 39 Postlethwait RW, Schauble JF, Dillon ML, Morgan J. Wound healing. II. An evaluation of surgical suture material. *Surg Gynecol Obstet* 108: 555-561, 1959
- 40 Brunius U, Zederfeldt B. Suture materials in general surgery. A comment. *Prog Surg* 8: 38-43, 1979